

The Minnesota Eye Foundation

proudly presents



PERSPECTIVES IN EYE CARE

Hosted By The
**MINNESOTA EYE
FOUNDATION**

Monday, May 20, 2024
Radisson Blu Hotel, Mall of America

COPE Activity ID # 128390



PERSPECTIVES IN EYE CARE

Hosted By The
MINNESOTA EYE
FOUNDATION

On behalf of the Minnesota Eye Foundation, welcome to the 2024 Perspectives in Eye Care program, a milestone occasion as we are celebrating 30 years! We are grateful for the continued support and participation received for **three decades** and honored you chose to attend this event to receive your continuing professional education.

Over the past 30 years, vision care has changed and evolved, and we have been right there providing insight, resources, and outstanding presenters from the community year in and out. Thank you for participating in this interactive and engaging forum. We have fun surprises during today's program, so we hope you take it all in!

You will have a wide array of learning opportunities with our esteemed faculty, time to connect with colleagues, and support the efforts of the Minnesota Eye Foundation (MEF)'s outreach and mission. The organization was established to enrich the quality of life of our community members through charitable outreach and continuing education in the field of vision care. Later today, you will have the opportunity to hear more about the Foundation's work, specifically The Vision Project and Strides 4 Sight. Please 'save the date' for Sunday, September 29, 2024, for our walk/run fundraising event, Strides 4 Sight, as we would welcome your participation and camaraderie outdoors at Normandale Lake Park Bandshell in Bloomington, MN.

Thank you for making an effort to be here today, and we are grateful for your commitment to continuing education and the Minnesota Eye Foundation's mission.

A handwritten signature in blue ink, appearing to read 'Omar Awad'.

Omar E. Awad, M.D., F.A.C.S
President, Minnesota Eye Foundation



MINNESOTA EYE
FOUNDATION

COPE CREDITS

We are using the following to verify attendance for this program.

QR Code

During each session or presentation, a QR code sheet will be passed around. Please use ARBO's OE tracker app to scan this QR Code. If you're unable to scan for any reason, simply write your name, OE tracker # and email on the page behind the QR Code sheet.

COPE SURVEY

As in years past, you will receive an email following the event asking you to complete our online Post-Event Feedback Survey. Your feedback is incredibly important to us, so please take a few minutes to complete this.

OE TRACKER ACCOUNT

ARBO will update your OE Tracker account once these credits have been issued.

QUESTIONS?

Contact us at info@mneyefoundation.com.



MINNESOTA EYE
FOUNDATION



OE TRACKER® Mobile App by ARBO

Instructions for Optometrists Attending CE Courses
(for iOS and Android)

Optometrists can use the OE TRACKER mobile app to record attendance at continuing education courses and receive instant course credit. You can also review your CE transcript, change your license information, and submit CE certificates for ARBO to add to your account. Not only is it easy, but the OE TRACKER mobile app is FREE and can be used by any optometrist with an OE TRACKER number. The OE TRACKER mobile app is available for iPhones/iPads and Android phones/tablets.

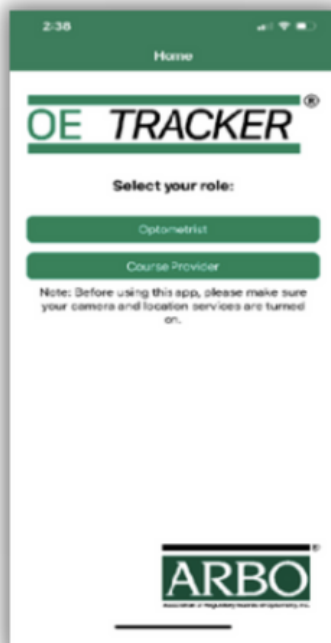
How to Get the OE TRACKER App:

iPhone/iPad: Go to the app store on your iPhone or iPad and search for “OE TRACKER.” Find the OE TRACKER app and touch to download.

Android Phone/tablet: Download the app from Google Play. Go to Google Play on your Android phone/tablet and search for “OE TRACKER.” Find the OE TRACKER app and touch the install button.

How to Use the OE TRACKER Mobile App:

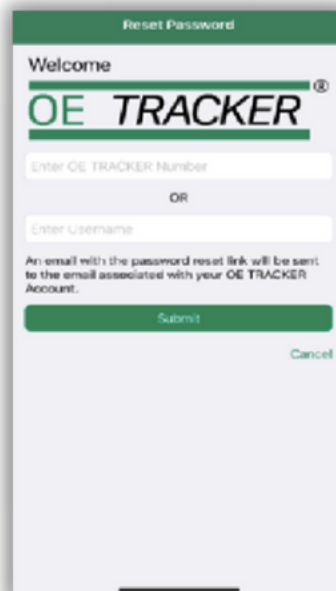
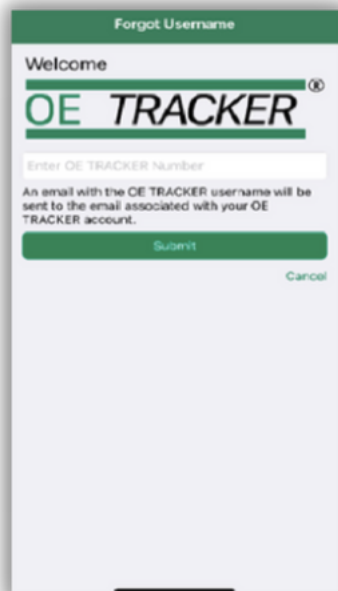
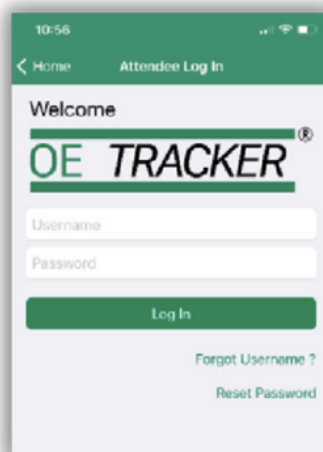Once you have downloaded the app, you will be asked you to select one of two roles to login: Optometrist or Course Provider.



Logging into the OE TRACKER mobile app as a Course Attendee:

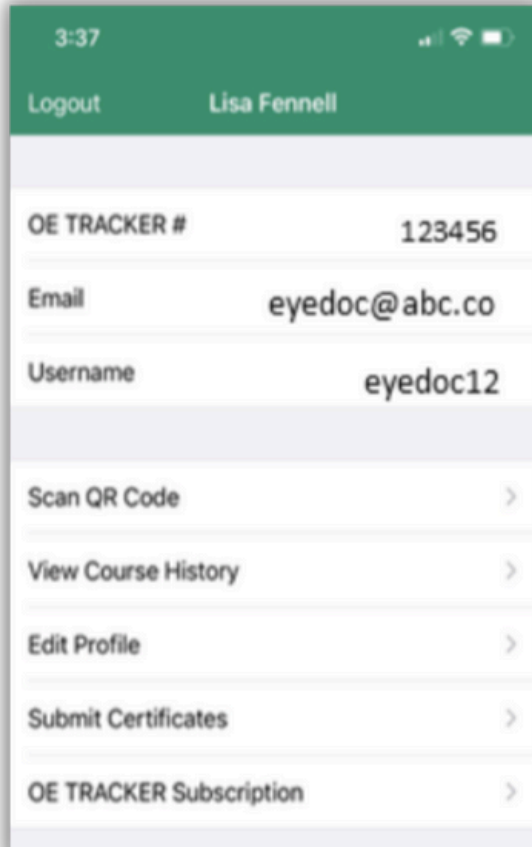Step One: Tap “Optometrist” if you are an optometrist that wants to record and track your CE credits.

You will need your OE TRACKER username and password. If you don't remember them, touch Forgot Username or Reset Password at the bottom of the screen. If you don't have an OE TRACKER account you can go to www.arbo.org to set it up. Here is how: Click on the OE TRACKER tab. A drop-down menu will appear. Next, click “Create OE TRACKER account” and complete the required form. Once your request is approved, you will receive an email with a link to set your username and password. Please allow 24-48 hours for your request to be approved.



Step Two: After you log in, the screen will display the following options:

- **OE TRACKER #**
- **Email address:** Please make sure your email address is correct so you receive notifications when courses are added to your account. Tap here to change your email address.
- **Username:** Tap here to change your username.
- **Scan QR Code:** You will use this to record attendance in real time at a CE meeting. If you are unable to use this feature, please make sure you have enabled camera access in your Settings.
- **View Course History:** Tap here to view your CE course history/transcript.
- **Edit Profile:** Tap here to review your personal information, add or change a license or update your address.
- **Submit Certificates:** Tap here to submit credits to ARBO to add to your OE TRACKER account.
- **OE TRACKER Subscription:** Tap here to review your subscription information or pay for your OE TRACKER subscription.

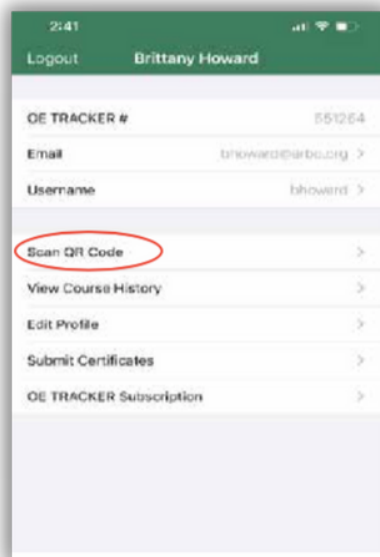


Recording Your Attendance at a CE Course:

PLEASE NOTE: In order to record your attendance using the OE TRACKER mobile app, the provider of the CE course must supply a course-specific QR code. After the course has been presented, the provider will post the QR code for attendees to scan.

If you have difficulty using the app you can ask the Course Provider to record your attendance using the OE TRACKER app on their device.

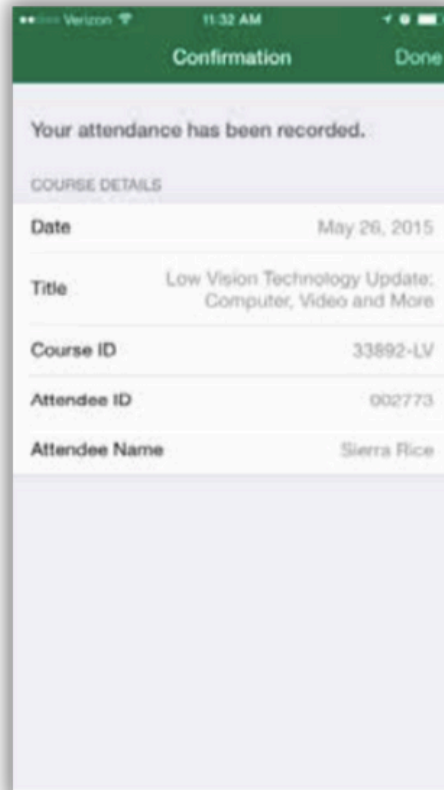On the Main screen, after you verify that your personal information is correct, touch “Scan QR Code” located below your e-mail address.



ARBO QR Code
(example)
COPE Course 48251-GO
COPE Event 110823



1. Your phone's camera will open and you will see “Scan QR Code” at the top of your screen.
2. Center the QR code on your screen and it will automatically scan. NOTE: If the code does not scan right away, try backing up your phone a little to make sure the entire QR code fits within the screen.
3. If you have scanned the QR code correctly, the Confirmation screen will appear, informing you that your attendance has been recorded in your OE TRACKER account.



4. You will also be sent an e-mail from OE TRACKER within the next few minutes advising you that your credit for the course has been entered into your account.

5. Touch "Done" at the top right side of the screen to return to the Main screen.

6. To exit, simply close the app. You will stay logged in to the app to scan another QR code. To log out of the app touch the "Logout" button.



AGENDA 2024

SESSION ONE

7:55 AM - Welcome & Announcements

8:00 AM - Neuro-ophthalmic Emergencies Involving the Afferent Visual Pathway: Variations on a Theme

Anne Abel, MD

8:50 AM - Oculoplastic Updates 2024

William Lipham, MD; Jill Melicher, MD; Krista Steward, MD

9:40 AM - Break in Exhibit Area

10:00 AM - Innovative Advancements and Treatments in Ocular Surface Disease

Ahmad Fahmy, OD, FAAO; Johnna Hobbs, OD; Mark Buboltz, OD, FAAO

10:50 AM - Updates in Pediatric Ophthalmology

Catherine Origlieri, MD; Tanya Glaser, MD

11:40 AM - The Vision Project & Strides 4 Sight

Omar Awad, MD, FACS; Matthew Field, MD, PhD; Mark Larson, MD

11:55 AM - Announcements

12:00 PM - Lunch in Exhibit Area

SESSION TWO

1:00 PM - Dr. Richard Lindstrom Remarks

Richard Lindstrom, MD

1:10 PM - Glaucoma Updates 2024

Glaucoma Case Management: Consensus or not??!! - Thomas Samuelson, MD

Tube Shunts in Glaucoma Care - Patrick Riedel, MD

The Suprachoroidal Space in Glaucoma Management - Christine Larsen, MD

Glaucoma and Pregnancy - Clara Choo, MD

Neovascular Glaucoma: An acute emergency - Chase Liaboe, MD

3:00 PM - Break in Exhibit Area

3:20 PM - Navigating Diagnostic and Therapeutic Challenges in Cataract Patients

Mark Hansen, MD; Omar Awad, MD; Sherman Reeves, MD, MPH

Panelists: David Hardten, MD, FACS; Elizabeth Davis, MD, FACS; Matthew Field, MD, MPH

4:10 PM - Advancements in the Treatment of Keratoconus

David Hardten, MD, FACS; Elizabeth Davis, MD, FACS

5:00 PM - Adjourn and Cocktail Reception



CONTENTS

SESSION ONE

Neuro-ophthalmic Emergencies Involving the Afferent Visual Pathway: Variations on a Theme	
Anne Abel, MD	13
Oculoplastic Updates 2024	
William Lipham, MD; Krista Stewart, MD; Jill Melicher, MD	14
Innovative Advancements and Treatments in Ocular Surface Disease	
Ahmad Fahmy, OD, FAAO; Johnna Hobbs, OD; Mark Buboltz, OD, FAAO	19
Updates in Pediatric Ophthalmology	
Tanya Glaser, MD; Catherine Origlieri, MD	24

SESSION TWO

Glaucoma Updates 2024	
Chase Liaboe, MD; Christine Larsen, MD; Clara Choo, MD; Patrick Riedel, MD; Thomas Samuelson, MD	31
Navigating Diagnostic and Therapeutic Challenges in Cataract Patients	
Mark Hansen, MD; Omar Awad, MD; Sherman Reeves, MD, MPH (Panelists: David Hardten, MD, FACS; Elizabeth Davis, MD, FACS; Matthew Field, MD, MPH)	40
Advancements in the Treatment of Keratoconus	
David Hardten, MD, FACS; Elizabeth Davis, MD, FACS	43

THANK YOU TO OUR SPONSORS

GOLD SPONSOR



CHERRY
OPTICAL LAB
See the difference.

BRONZE SPONSORS

abbvie



AMGEN

BAUSCH+LOMB

Apellis



CooperVision®

GLAUKOS
TRANSFORMING VISION



Better Sight.
Better Life.

HEIDELBERG
ENGINEERING

Johnson & Johnson VISION

imprimis ^{Rx}
A HARROW COMPANY

MacuHealth

LensWorks

Optical Professionals
of Minnesota

neuroLens®

RXSIGHT

SUN
OPHTHALMICS

TARSUS

VIATRIS™


WALMAN
INSTRUMENTS

WALMAN
OPTICAL



**CLAREON®
COLLECTION**

THE CLAREON® COLLECTION IS COMPLETE



CLAREON® TORIC Glistening-free* BioMaterial with unrivaled rotational stability† and predictable performance.¹⁻⁶

CLAREON® VIVITY® The first and only non-diffractive wavefront shaping PCIOL with exceptional clarity,^{2,3*} monofocal-quality distance visual acuity, excellent intermediate vision, and functional near vision.[‡]

CLAREON® PANOPTIX®

A full range of vision with exceptional clarity that lasts.^{7, 8*}

45% of patients are willing to upgrade to an ATIOL, however, only **18%** are currently receiving one. Educate your patients on Alcon ATIOLs to meet their expectations.⁹

Learn more at ClareonIOL.com

* Defined as modified Miyata grade 0, <25mv/mm² over 3 years (n=138), and over 9 years (n=20), respectively. ATIOL=Advanced Technology IOL.
 † In vitro comparison, P <0.05.
 ‡ Results from a prospective, randomized, parallel group, subject- and assessor-masked, multisite trial of 107 subjects bilaterally implanted with the AcrySof® IQ Vivity® Extended Vision IOL and I13 with the AcrySof® IQ IOL with 6 months follow-up.
 § Snellen VA was converted from logMAR VA. A Snellen notation of 20/20-2 or better indicates a logMAR VA of 0.04 or better, which means 3 or more of the 5 ETDRS chart letters in the line were identified correctly.
 ¶ N=297.
 || Q4 2022.

IMPORTANT PRODUCT INFORMATION: CLAREON® FAMILY OF IOLS

CAUTION: restricts these devices to sale by or on the order of a physician.

INDICATION: Clareon® intraocular lenses (IOLs) Clareon® Aspheric Hydrophobic Acrylic Clareon® Aspheric Toric IOLs family of includes the and , the Clareon® PanOptix® Trifocal Hydrophobic IOL Clareon® PanOptix® Toric Clareon® Vivity® Extended Vision Hydrophobic Posterior Chamber IOL Clareon® Vivity® Toric IOLs . Each of these IOLs is indicated for visual correction of aphakia in cataract surgery. In addition, the are indicated to correct pre-existing corneal astigmatism at the time of cataract surgery. The Clareon® PanOptix® lenses mitigates the effects of presbyopia by providing improved intermediate and near visual acuity, while maintaining comparable distance visual acuity with a reduced need for eyeglasses, compared to a monofocal IOL. The Clareon® Vivity® lens mitigates the effects of presbyopia by providing an extended depth of focus. Compared to an aspheric monofocal IOL, the lens provides improved intermediate and near visual acuity, while maintaining comparable distance visual acuity. All of these IOLs are intended for placement in the capsular bag.

WARNINGS / PRECAUTIONS:

General cautions for all Clareon® IOLs: Careful preoperative evaluation and sound clinical judgment should be used by the surgeon to decide the risk / benefit ratio before implanting any IOL in a patient with any of the conditions described in the Directions for Use that accompany each IOL. Physicians should target emmetropia, and ensure that IOL centration is achieved.

For the Clareon® Aspheric Toric, PanOptix® Toric and Vivity® Toric IOLs, the lens should not be implanted if the posterior capsule is ruptured, if the zonules are damaged, or if a primary posterior capsulotomy is planned. Rotation can reduce astigmatic correction; if necessary lens repositioning should occur as early as possible prior to lens encapsulation.

For the Clareon® PanOptix® IOL, some visual effects may be expected due to the superposition of focused and unfocused multiple images. These may include some perceptions of halos or starbursts, as well as other visual symptoms. As with other multifocal IOLs, there is a possibility that visual symptoms may be significant enough that the patient will request explant of the multifocal IOL. A reduction in contrast sensitivity as compared to a monofocal IOL may be experienced by some patients and may be more prevalent in low lighting conditions. Therefore, patients implanted with multifocal IOLs should exercise caution when driving at night or in poor visibility conditions. Patients should be advised that unexpected outcomes could lead to continued spectacle dependence or the need for secondary surgical intervention (e.g., intraocular lens replacement or repositioning). As with other multifocal IOLs, patients may need glasses when reading small print or looking at small objects. Posterior capsule opacification (PCO), may significantly affect the vision of patients with multifocal IOLs sooner in its progression than patients with monofocal IOLs.

For the Clareon® Vivity® IOL, most patients implanted with the Vivity® IOL are likely to experience significant loss of contrast sensitivity as compared to a monofocal IOL. Therefore, it is essential that prospective patients be fully informed of this risk before giving their consent for implantation of the Clareon® Vivity® IOL. In addition, patients should be warned that they will need to exercise caution when engaging in activities that require good vision in dimly lit environments, such as driving at night or in poor visibility conditions, especially in the presence of oncoming traffic. It is possible to experience very bothersome visual disturbances, significant enough that the patient could request explant of the IOL. In the parent AcrySof® IQ Vivity® IOL clinical study, 1% to 2% of AcrySof® IQ Vivity® IOL patients reported very bothersome starbursts, halos, blurred vision, or dark area visual disturbances; however, no explants were reported.

Prior to surgery, physicians should provide prospective patients with a copy of the Patient Information Brochure available from Alcon informing them of possible risks and benefits associated with these IOLs.

ATTENTION: Reference the Directions for Use labeling for each IOL for a complete listing of indications, warnings, and precautions.

REFERENCES: 1. Werner L, Thattamla I, Ong M, et al. Evaluation of clarity characteristics in a new hydrophobic acrylic IOL. J Cataract Refract Surg. 2019;45:1490-1497. 2. Oshika T, Fujita Y, Inamura M, Miyata K. Mid-term and long-term clinical assessments of a new 1-piece hydrophobic acrylic IOL with hydroxyethyl methacrylate. J Cataract Refract Surg. 2020 May;46(5):682-687. 3. Maxwell A, Suryakumar R. Long-term effectiveness and safety of a three-piece acrylic hydrophobic intraocular lens modified with hydroxyethyl-methacrylate: an open-label, 3-year follow-up study. Clin Ophthalmol. 2018;12:2031-2037. 4. Alcon Data on File, 2017. 5. Lane S, Collins S, Das KK, Maass S, Thattamla I, Schatz H, Van Noy S, Jain R. Evaluation of intraocular lens mechanical stability. J Cataract Refract Surg. 2019 Apr;45(4):501-506. 6. Clareon® Vivity® Extended Vision Hydrophobic IOL (CNWETO) Directions for Use – US. 7. Clareon® PanOptix® Trifocal Hydrophobic Acrylic IOL Model: CNWTO DFU. 8. Lehmann R, Maxwell A, Lubeck DM, Fong R, Walters TR, Fakadej A. Effectiveness and Safety of the Clareon® Monofocal Intraocular Lens: Outcomes from a 12-Month Single-Arm Clinical Study in a Large Sample. Clin Ophthalmol. 2021;15:1647-1657. Published 2021 Apr 20. 9. Alcon Data on File, 2022.



DID YOU KNOW?

- We are “Seekers of Better” from boldly pioneering new processes to our obsession with cultivating happy people. We offer an accelerated turn-around time with lenses crafted to meet the highest-quality standards by experts who have received the same certifications as opticians. All this in an effort to give eye care professionals more ways to say “Yes” to their patients.
- COL is family-owned and independently operated
- COL is a full digital and freeform surfacing laboratory
- COL has a Full Service Anti-Reflective and Mirror Processing Facility on-site (producing both Crizal and Cherry Brands)
- The average turn-time for a job produced at COL is 3-5 days
- COL has many ABO-certified Customer Service agents as well as ABO-certified managers, team leads and production team members
- COL offers many forms of communication to best suit your team’s needs, including SpecCheck Chat, Slack, email, and phone
- COL was the first wholesale optical laboratory to offer a Truly Unlimited Warranty Policy (lifetime warranty on all products we produce)
- COL covers previous lab warranties (Cherry Optical Lab assumes the warranty on all orders placed with your previous lab)
- You have 101 days to take advantage of our Unbelievable Multi-Pair Discount (highest priced job will be billed inclusive of End of Month Discount, all other orders billed at 50% discount)
- COL offers complimentary employee orders for all supportive customers
- COL has a competitively priced Kids Package
- COL offers specialty lenses including Avulux and Shaw Lenses



CHERRY
OPTICAL LAB

See the difference.

At Cherry Optical Lab we pride ourselves on being a top-notch, innovative and service-driven Independent Optical Laboratory. There surely are larger optical laboratories, but the technology and capabilities of our skilled craftsmen ensures no one is better than us.



SESSION ONE



Anne Abel, M.D.

Anne Abel, MD
Hennepin Healthcare:
Neuro-Ophthalmologist and Cataract
Surgeon Department of Ophthalmology

Neuro-ophthalmic Emergencies Involving the Afferent Visual Pathway: Variations on a Theme

COPE Course ID # 91209-NO

Course Description

Utilizing illustrative cases, we will discuss the evaluation and recognition of neuro-ophthalmic emergencies involving the afferent visual pathways. Clinical differentiation of various causes of optic neuropathy will be explored and treatment paradigms will be discussed.

Course Objective

1. Review the evaluation of bilateral optic disc edema and the radiographic findings of increased intracranial pressure.
2. Discuss atypical clinical findings in patients with suspected papilledema.
3. Review the clinical features of typical versus atypical optic neuritis and discuss systemic diseases that may present with acute optic neuropathy



**MINNESOTA EYE
FOUNDATION**



SESSION ONE



William J. Lipham, M.D.

Minnesota Eye Consultants
Ophthalmic Plastics, Orbit
and Reconstructive Surgery



Krista J. Stewart, M.D.

Minnesota Eye Consultants
Ophthalmic Plastics, Orbit
and Reconstructive Surgery



Jill S. Melicher, M.D.

Minnesota Eye Consultants
Ophthalmic Plastics, Orbit
and Reconstructive Surgery

Oculoplastics Updates 2024

COPE Course ID # 91239-TD

Course Description

This lecture will discuss the pathophysiology, etiology, epidemiology, prognosis, patient education, clinical presentation, physical exam findings, associated disorders and treatment and management of Floppy Eyelid Syndrome (FES). It will also note that internal brow lifting procedures performed through an eyelid crease incision are now considered cosmetic in nature by Medicare and all insurance carriers. The attendees will also learn through case presentation of three Oculoplastic Cases where the initial presentation led to clinical misdiagnosis. The presenter will walk through critical clinical thinking using real life examples of clinical conundrums leading to misdiagnosis.

Course Objective

1. Understand the pathophysiology etiology, epidemiology, and prognosis of FES.
2. Recognize how patients present clinically as well as other conditions associated with FES.
3. Learn how to educate your patients with these conditions as well as treat and manage FES and understand when it is appropriate to refer them to an oculoplastic surgeon.
4. Presentation and management of a pigmented eyelid lesion resulting in the misdiagnosis of malignant melanoma of the eyelid.
5. Presentation of a nodular eyelid lesion resulting in the misdiagnosis of malignant lymphoma of the eyelid.
6. Presentation of an orbital lesion clinically consistent with orbital hemangioma with clinical presentation consistent with rhabdomyosarcoma requiring systemic medication and management.
7. Presentation will discuss medical management of neurotrophic keratopathy patients including insulin, Oxervate and contact lens use.

Floppy Eyelid Syndrome and Cosmetic Considerations

William Lipham, M.D.

1. Financial Disclosures
2. Floppy Eyelid Syndrome: Background
 - i. Floppy Eyelid Syndrome (FES) was first described by Culbertson and Ostler in 1981
 - ii. Common Characteristics:
 1. Overweight men
 2. Floppy, rubbery, easily everted upper eyelids
 3. Chronic papillary conjunctivitis of the upper palpebral conjunctiva
 - iii. Listen to your patient! (Or at least their symptoms)
 1. Typically, they describe redness and discharge that is worse upon awakening
 2. Frequently they have tried numerous drops, AT's, NSAID's, steroids and antibiotics with no relief
 3. More frequent in patients who are obese.
 4. Is associated with Obstructive Sleep Apnea (OSA)
 5. Ask them if they sleep on their side or their stomach, snore, or if they use a CPAP device
 - iv. Pathophysiology
 1. Patients with OSA:
 - a. Have intermittent airway obstruction when sleeping on their back
 - b. To maintain their airway, they adapt by sleeping on their side or stomach to open their airway
 2. OSA can lead to:
 - a. Awakening
 - b. Thick mucoid discharge
 - c. Sleep History:
 - i. Snoring
 - ii. Side or stomach sleepers
 - iii. Dependent side is worse
 - d. Past Medical History:
 - i. OSA and use of CPAP
 - ii. Congestive Heart Failure (CHF)
 - iii. Hypertension

Notes

3. Physical Examination

- a. Lax upper eyelid that everts easily when pulled towards the eyebrow.
- b. Soft rubbery tarsal plate that can be folded upon itself. Stringy, mucoid conjunctival discharge
- c. Eyelash ptosis with loss of eyelash parallelism and eversion.
- d. Periorbital involuntional Changes:
 - i. Brow Ptosis
 - ii. Dermatochalasis
 - iii. Upper eyelid ptosis
 - iv. Horizontal lower eyelid laxity
 - v. Lacrimal gland prolapse.

4. Patient Education

- a. Significance of Sleeping face down or buried in the pillow/mattress
- b. Possibility of associated OSA and need for sleep study/CPAP device
- c. Connection between eye rubbing, keratoconus and FES
- d. Treatment options

5. Treatment and Management

- a. Topical lubrication
 - i. AT during daytime
 - ii. Erythromycin ung qHS
- b. Either taping lids shut at night or using eye shields to reduce lid eversion
- c. Lateral Tarsal Strip Procedure (LTS)
- d. Lateral Tarsal Resection

You've got Nerve: An Update on Oculoplastic Management of Neurotrophic Keratopathy

Krista J. Stewart, M.D.

1. Case Presentation: Neurotrophic keratopathy post brain tumor resection
 - i. Patient presentation: recurrent corneal ulcerations post brain tumor resection
 1. Clinical findings
 2. Initial diagnostic assessment
 3. Discussion of initial treatments including
 - i. Description of healing progression and surgical intervention
 - ii. Characteristics of 5th and 7th nerve palsy combined
2. Case Presentation: Diabetic neurotrophic keratopathy
 - i. Patient presentation: bilateral corneal thinning and recurrent preformation with visual outcomes
 1. Clinical findings
 2. Initial diagnostic assessment
 3. Discussion of initial medical and procedural treatments
 - ii. Surgical approach
 - iii. Characteristics of diabetic neurotrophic keratopathy

Notes

Making the Misdiagnosis: Lessons Learning from Management Challenges; Oculoplastic Surgery M&M

Jill S. Melicher, M.D.

1. Case Presentation: Pigmented Eyelid Lesion
 - i. Clinical findings
 - ii. Initial diagnostic assesment
 - iii. Discussion of initial misdiagnosis of seborrheic keratosis
2. Description of lesion progression
3. Characteristics of malignant melanoma
4. Findings contributing to misdiagnosis
5. Multidisciplinary approach to the management of melanoma
 - i. Lesion excision and reconstruction
6. Case Presentation: Eyelid Lymphoma
 - i. Patient persenation: nodular lower eyelid lesion
 1. Clinical findings
 2. Initial diagnostic assessment
 3. Discussion of initial misdiagnosis of chalazion
 - ii. Description of lesion progression
 - iii. Characteristics of eyelid lymphoma
 - iv. Findings contributing to misdiagnosis
 - v. Multidisciplinary approach to the management of lymphoma
7. Case Presentation: Orbital rhabdomyosarcoma
 - i. Patient presentation: superomedial orbital mass
 1. Clinical findings
 2. Initial diagnostic assessment
 3. Discussion of initial misdiagnosis of hemangioma
 - ii. Description of lesion progression
 - iii. Characteristics of orbital rhabdomyosarcoma
 - iv. Findings contributing to misdiagnosis
 - v. Multidisciplinary approach to the management of rhabdomyosarcoma
8. Questions

Notes



SESSION ONE



Ahmad Fahmy, O.D., FAAO

Minnesota Eye Consultants
Primary Eye Care and Dry
Eye Specialist



Johnna Hobbs, O.D.

Minnesota Eye Consultants
Primary Eye Care and Dry
Eye Specialist



Mark Buboltz, O.D., FAAO

Minnesota Eye Consultants
Primary Eye Care, Specialty Contact
Lenses, and Dry Eye Specialist

Innovation Advancements and Treatments in Ocular Surface Disease

COPE Course ID # 90844-TD

Course Description

This lecture will focus on innovative clinical research and treatments in Ocular Surface Disease (OSD). By utilizing case-based learning, this course will highlight pertinent clinical studies and new, innovative treatments.

Course Objective

1. Review the key features of innate and adaptive immunity in dry eye disease.
2. Identify the key relationships between gut microbiota and adaptive immune cells.
3. Identify the key relationships between gut microbiota and innate immune cells.
4. Understand how antibiotic-induced gut dysbiosis can lead to increased ocular surface inflammation.
5. Review effective in-office treatments and when best to incorporate them into the treatment plan.
6. Identify new, promising treatments in the OSD pipeline



Innovative Advancements and Treatments in Ocular Surface Disease

Ahmad Fhamy, OD, FAAO;

Johnna Hobbs, OD;

Mark Buboltz, OD, FAAO

1. Inflammatory pathways in Ocular Surface Disease (OSD)

a. Ocular surface desiccation and osmotic stress induced by multiple factors

b. Disease perpetuation by ongoing, vicious cycle:

i. Inflammation, hyperosmolarity, tear film instability

ii. Disease perpetuation triggers key, ongoing immune processes

1. Inflammatory cytokines involved in innate immune response

2. Adaptive T-cells in adaptive immune response

3. Inflammatory cytokines and chemokines involved in neuro-sensitization

a. Leading to patient discomfort, irritation symptoms

b. Most patients have episodic exacerbation of symptoms:

i. Flare – can be triggered by many factors

1. Ocular surgery

2. Low-humidity environment

3. Ocular injury (trauma, chemical injury)

4. Contact lens use

5. Toxic oral or topical medications

a. Topical polypharmacy

6. Allergens

7. Exacerbation of auto-immune disease

ii. Pathophysiology of a flare

1. In chronic OSD:

a. Adaptive immune response already active – pathogenic T-Cells

i. Leads to rapid increase of inflammation at lower thresholds.

4. Inflammatory cycle persists unless disrupted by introduction of anti-inflammatory treatment.

Notes



2. Gut microbiota and the immune system - uncovering a key link:
 - a. Major pathways between gut microbiota and adaptive immune cells
 - b. Major pathways between gut microbiota and innate immune cells
3. Gut-Eye Axis
 - a. Autoimmune Uveitis
 - b. Age-Related Macular Degeneration
 - c. Primary Open-Angle Glaucoma
 - d. Ocular Surface Disease
4. Systemic impact of gut microbiota
 - a. Immunological pathway alterations are a result of distinct gut microbiota compositional changes
 - i. Central nervous system
 1. Gut derived neurotransmitters and neuropeptides
 2. Specific gut species linked with amelioration of depression and anxiety
 - a. Anxiety and depression: common OSD co-morbid conditions
5. Key communication routes impacting the Ocular Surface
 - a. Microbial Diversity and Dry Eye
 - i. Ocular surface microbiota overview
 - ii. Differences in microbiota in dry eye vs healthy eyes
 - b. Sjogren's Syndrome
 - i. Gut dysbiosis in SS patients
 - ii. Mechanism of gut-eye/lacrimal gland axis
 - c. Meibomian Gland Dysfunction
 - i. Changes in gland morphology
 - ii. Changes in ocular surface/glandular microbiota
6. Emerging Therapeutics
 - a. Probiotics/Prebiotics
 - i. Effectiveness of oral probiotics and changing gut microbiota
 - ii. Topical probiotics
 1. Treatment of vernal keratoconjunctivitis
 - iii. Bacterial products as a treatment?
 1. Toll-like receptors
 - b. Fecal Microbiota Transplantation
 - c. Role of Oral Antibiotics
 - i. Damage to Gut Microbial Diversity
 - ii. Can microbial diversity be restored after oral/IV antibiotics
 - iii. Are some oral antibiotics damaging to gut microbial diversity?

7. Case Presentation:

a. Pertinent history:

- i. 55-year-old male patient
- ii. Refractory to multiple single therapies to treat OSD
 1. Could not tolerate Doxycycline
- iii. Mostly struggles with irritation, foreign body sensation
- iv. Onset of symptoms 10 years ago
- v. Struggles with depression
- vi. Significant co-morbid facial rosacea
- vii. Current smoker – cigars
- viii. Overall unhealthy diet
 1. Pro-inflammatory, fast food

b. Clinical evaluation:

- i. Hyperosmolar both eyes, strong (+) MMP-9 both eyes
- ii. Significant eyelid telangiectasia, conjunctival injection each eye
- iii. Diffuse punctate epithelial keratopathy (PEK) each eye
- iv. Floppy eyelid syndrome

c. Treatment:

- i. Chronic anti-inflammatory immunomodulators
- ii. Nutritionist

d. Follow up:

- i. Introduced pro-biotic through his nutritionist
 1. This is the key treatment that resulted subjective improvement
- ii. Osmolarity and MMP-9 normal
- iii. Mild, improved PEK and significantly improved conjunctival injection
- iv. Future treatments of similar patients
 1. Likely to be able to provide even more customized gut flora modulation in patients with additional systemic and ocular co-morbidities.

8. Innovation in OSD Treatments

a. Anti-inflammatories

b. Lid Margin Treatments

- i. Eyelid debridement, Microblepharoexfoliation (MBE)

c. Thermal pulsation

- i. Combined with evacuation of the meibomian glands with eyelid expression
- ii. Combined with IPL
- iii. Frequency of Treatment
- iv. Treatment options in this category

1. Matching the OSD patient with the best treatment



- d. Eyelid expression
 - i. Multiple tools now available
 - ii. Frequency of treatment
- e. Meibomian Gland Probing
 - i. Proper technique
 - ii. Frequency of treatment
 - iii. Combined with thermal pulsation and IPL
 - iv. Proper anesthesia
 - v. Drug delivery into the meibomian glands
 - 1. Stem cells
 - 2. Platelet Rich Plasma (PRP)
- f. Intense Pulsed Light (IPL) and IRPL
 - i. General treatment approach
 - ii. Combined with other procedures
 - iii. Frequency
 - iv. Unique treatment benefits
- g. Low Level Light Therapy
 - i. Fairly new treatment option
 - ii. Changes in tear break-up time, OSDI, MG score in early clinical studies
 - 1. Karl Stonecipher, et al. LLLT as an adjunct treatment for MGD. Acta Scientifica Ophthalmology
- h. Treatment of Eyelid Abnormalities
 - i. Floppy Eyelid Syndrome
 - ii. Blepharospasm
 - iii. Exposure / ectropion
 - iv. Eyelid imbrication
- i. Punctal Plugs
 - i. Extended v. dissolving plugs
 - ii. Tear meniscus height
 - iii. Micro-Flow
- j. Dilation and irrigation
 - i. Proper technique
 - ii. Importance of tear clearance
 - iii. Sinus infections
- k. Compounded medications
 - i. Blood derived eye drops
- 9. Promising Pipeline Medications
 - a. Mechanisms of action
 - b. Timeline for approval
 - c. When to use in clinical practice

Notes



SESSION ONE



Tanya Glaser, M.D.

Northwest Eye
Pediatric Ophthalmology and
Pediatric Eye Alignment Specialist



Catherine Origlieri, M.D.

Northwest Eye
Pediatric Ophthalmology and
Pediatric Eye Alignment Specialist

Updates in Pediatric Ophthalmology

COPE Course ID # 90870-FV

Course Description

This course will review current updates in pediatric ophthalmology including low-dose atropine for the treatment of myopia progression, advances in amblyopia treatment using digital dichoptic therapies, new statewide newborn CMV screening, and developments in pediatric cataract evaluation.

Course Objective

1. Attendees will learn the rationale for using low-dose atropine for myopia control based on the review of key clinical trials.
2. They will be able to describe treatment for amblyopia with dichoptic digital therapies.
3. Attendees will better understand the state-level changes in congenital CMV screening and potential ocular findings associated with congenital CMV.
4. They will learn about a disease called cerebrotendinous xanthomatosis (CTX) and describe how to screen for this condition when examining children and young adults with cataracts.



**MINNESOTA EYE
FOUNDATION**

Updates in Pediatric Ophthalmology

Tanya Glaser, M.D.;
Catherine Origlier, M.D.

1. Myopia

- a. 50% world population by 2050
- b. High myopia: 10% world population by 2050
- c. Associations:
 - i. Presenile cataract
 - ii. Glaucoma
 - iii. RD
 - iv. Myopic maculopathy (choroidal neovascularization, myopic macular degeneration, macular hemorrhage)
 - v. Strabismus (heavy eye syndrome)

2. Low-dose Atropine for Treatment of Myopia Progression

- a. Non-selective muscarinic blocker
- b. Unknown mechanism in myopia control – thought to inhibit scleral thinning/stretching and thereby inhibit eye growth

3. ATOM1

- a. Atropine 1% over 2 years slowed myopia progression by 77% and reduced axial length elongation
- b. Adverse effects

4. ATOM2

- a. Atropine 0.5%, 0.1%, 0.01% over 2 years slowed myopia progression by 75%, 70%, 60%, respectively
- b. Rebound effect associated with the higher doses
- c. After 5 years, myopia progression remained lowest in the 0.01% group

5. LAMP

- a. Atropine 0.05%, 0.025%, 0.01% over 1 year slowed myopia progression by 67%, 43%, and 27%, respectively
- b. Similar efficacy at year 2 for 0.05% and 0.025%, and slightly better for 0.01%
- c. After 3 years, myopia progression remained lowest in 0.05% group
- d. 5-year data is currently in publication

Notes

6. Amblyopia

- a. Unilateral or bilateral reduction of best-corrected visual acuity in the setting of an otherwise normal eye
- b. Developmental disorder of the central nervous system that results from the abnormal processing of visual images, leading to reduced visual acuity
- c. Refractive: Anisometropic, High bilateral refractive (isoametropic)
- d. Strabismic
- e. Visual deprivation: Media opacities, Ptosis

7. Traditional amblyopia treatment

- a. Optical correction
- b. Patching
- c. Atropine

8. Dichoptic digital therapies

- a. To treat amblyopia in children who have binocularity (i.e. no strabismus or small angle strabismus)
- b. High-contrast image is presented to the amblyopic eye and low-contrast image to the fellow eye
- c. Initial data was not promising, however improved outcomes have been associated with more recently developed technologies, e.g. tablet, virtual reality headset
- d. Research is ongoing

9. Congenital CMV

- a. The incidence of congenital CMV infection ranges from 0.5% to 2%
- b. Up to 85% of infected newborns are asymptomatic
- c. Symptoms of congenital CMV infection include microcephaly, jaundice, hepatosplenomegaly, petechiae, hearing loss and chorioretinitis
- d. Long-term sequelae include progressive hearing loss, neurodevelopmental disabilities
- e. Long term ocular findings include chorioretinitis, optic atrophy, strabismus, and cortical visual impairment

10. Chorioretinitis

- a. Chorioretinitis is not generally believed to develop later if not present in the neonatal period
- b. Though there exists rare case reports of late onset or reactivation
- c. Typically, without hemorrhages (hemorrhages typical in immunocompromised individuals)



11. Developments in Minnesota

- a. Dr. Mark Schleiss at the U of MN and his team developed a test for congenital CMV using dried blood spot taken at birth (standard to check for more than 60 other diseases)
- b. Minnesota legislature passed the Vivian Act in 2021, advocated for by parents, the law is meant to promote education, awareness, and early detection of congenital CMV
- c. In January 2022, the Advisory Committee recommended adding congenital CMV to the newborn screening panel.
- d. On February 6, 2023, Minnesota became the first state in the nation to screen every newborn for CMV.
- e. It is estimated that up to 300 babies out of 65,000 born each year in Minnesota will have congenital CMV

12. In Real Time

- a. Dr. Mark Schleiss at the U of MN and his team developed a test for congenital CMV using dried blood spot taken at birth (used for standard newborn screen for 60+ other diseases)
- b. Follow-up urine testing within 21 days will determine whether the baby was infected with cytomegalovirus at birth
- c. If positive, patient then referred for additional hearing testing, head US and ophthalmologic exam

13. Review of literature

- a. "Long-term Visual and Ocular Sequelae in Patients with Congenital Cytomegalovirus Infection"
- b. "Ophthalmologic findings in children with congenital cytomegalovirus infection"

14. Follow Up and Screening

- a. Influx of babies with positive congenital CMV testing
- b. Asymptomatic infants still at risk for hearing loss
- c. Asymptomatic infants are low risk for ocular findings
- d. No current guidelines for how often to repeat ocular exam
 - i. If immunocompetent then exam within 3 months of birth, then 3-6 months after that to confirm no findings, then every 6-12 months.
 - ii. If immunocompromised then scleral depressed exam
- e. More updates coming soon

15. Case Presentation – Juvenile Cataracts and Cerebrotendinous Xanthomatosis (CTX)
 - a. Review case presentation, ocular exam/findings, query audience on next steps
 - b. Suggest additional history that may be helpful: jaundice after birth, history of diarrhea, gait or balance issues, history of xanthomas.
16. Cerebrotendinous Xanthomatosis (CTX)
 - a. Cerebrotendinous Xanthomatosis (CTX) is a rare, likely underdiagnosed disease
 - b. Autosomal recessive metabolic storage disorder
 - c. Caused by mutations in the CYP27A1 gene, leading to a deficiency in sterol 27- hydroxylase, an important enzyme in bile acid synthesis
 - d. This deficiency leads to a buildup of 5-alpha-cholestanol, which affects the brain, connective tissue, and the crystalline lens
 - e. CTX has variable onset and severity
 - f. Irreversible neurological deterioration is present in late disease
17. CTX symptoms and signs
 - a. Neonatal jaundice
 - b. Chronic diarrhea
 - c. Gait or balance issues, progressive neurologic changes
 - d. Xanthomas
18. How common is CTX?
 - a. Estimated prevalence, 3 to 5 per 100 000
 - b. Barriers to diagnosis:
 - i. Variability in phenotype
 - ii. Can be mild initially
 - c. Often long delay (decades) between symptom onset and diagnosis
 - d. Diagnosis often occurs after irreversible neurological damage
19. Literature review
 - a. "Prevalence of Cerebrotendinous Xanthomatosis Among Patients Diagnosed with Acquired Juvenile-Onset Idiopathic Bilateral Cataracts"
 - b. 1.8% prevalence among children and young adults with bilateral cataracts compared to 0.00005% in the general population.

20. Importance of Considering CTX when evaluating Juvenile-onset Cataracts

- a. Juvenile Cataracts may be the presenting sign in this condition. Early detection can prevent later symptoms and neurological decline.
- b. Long-term treatment includes supplementation with supplementation of chenodeoxycholic acid (CDCA), which normalizes bile acid synthesis
- c. Treatment in presymptomatic individuals prevents clinical manifestations
- d. Early treatment in symptomatic patients can limit progression and reverse neurologic symptoms • It is our job as eye care providers to keep CTX in mind when evaluating Juvenile or early-onset cataracts.
- e. By making this diagnosis we can have a huge impact in a patient's life

21. Q&A

Notes

STRIDES 4 SIGHT 5K & KIDS FUN RUN

A community event benefiting
The Vision Project

Join us in changing lives, one eye at
a time, through the **Strides 4 Sight**
5k Walk/Run and Kids Fun Run!

SUNDAY, SEPTEMBER 29

8:00 AM Check in

8:30 AM Kids Fun Run

Silent Auction Opens

9:00 AM 5K Run/Walk

9:45 AM Auction Closes

10:00 AM Awards*

**Silent Auction will take place onsite to raise additional
funds for the Minnesota Eye Foundation's Vision Project*



Normandale Lake Bandshell
5901 W 84th St.
Bloomington, MN 55438

\$30

5K RUN/WALK

**Day of Event Registration Fee for 5K
Run/Walk is \$40/person.*

\$15

**KIDS 12 AND UNDER
FUN RUN**

**Processing fee will apply for all registrants.*



STRIDES 4 SIGHT
MINNESOTA EYE FOUNDATION



MINNESOTA EYE
FOUNDATION

For sponsorship information,
contact Maura at mjmittchell@mneye.com

REGISTER TODAY!

www.strides4sight.com

Silent Auction



**PERSPECTIVES
IN EYE CARE**

Hosted By The
**MINNESOTA EYE
FOUNDATION**

Bottles of 2014 Caymus Special Select Wine (6)

Bottles of Hardten Family Vineyards First Reserve (3)

Bottles of Hardten Family Vineyards Dinner Belle (3)

LASIK Procedure by Fellow

Dinner in David & Christine Hardten's Wine Cellar

Pickleball Package

Kids Create Studio Arts & Crafts Package

Coach Large Leather Work Bag

Minnesota Timberwolves Basketball Tickets (2)

Minnesota Wild Hockey Tickets (2)

Pontoon Boat Excursion on Snail Lake, Shoreview, MN

\$100 Gift Card to Spoon & Stable

*All proceeds will directly benefit the Vision Project
offering surgical eye care to patients in need.*

BID TODAY!

**Scan the QR code or click the link below to bid online! Bidding
will be available on Monday at the event, closing at 5:30 pm.**



<https://www.32auctions.com/Perspectives2024Auction>



SESSION TWO



Chase A. Liaboe, M.D.

Minnesota Eye Consultants
Glaucoma & Cataract
Specialist



Christine L. Larsen, M.D.

Minnesota Eye Consultants
Glaucoma & Cataract
Specialist



Clara M. Choo, M.D.

Minnesota Eye Consultants
Glaucoma & Cataract
Specialist



Patrick J. Riedel, M.D.

Minnesota Eye Consultants
Glaucoma, Cataract and
Refractive Specialist



**Thomas W.
Samuelson, M.D.**

Minnesota Eye Consultants
Cornea, Cataract
& Refractive Specialist

Glaucoma Updates 2024

COPE Course ID # 90922-GL

Course Description

Attendees will get an overview of current medication management options as well as current surgical management options in glaucoma care. We will also discuss the diagnosis, etiology, triage, of management of neovascular glaucoma. We will also discuss management options of glaucoma during pregnancy as well as a review of how surgeries performed within the suprachoroidal space may be a potential option for lowering IOP.

Course Objective

1. Overview of current glaucoma medication management options and surgical management options as well as their advantages and disadvantages.
2. Briefly review the anatomy of the suprachoroidal space and how it may be utilized to lower IOP.
3. Discuss pre-conception counselling and examination paradigms in glaucoma and pregnancy.
4. Discuss how to recognize and diagnose neovascular glaucoma with a multimodal exam, including detailed history and exam.



**MINNESOTA EYE
FOUNDATION**

Neovascular Glaucoma: An acute emergency

Chase A. Liaboe

- a. Overview of Neovascular glaucoma
 - i. Etiology
 - ii. Clinical presentation
 - iii. Exam
 - iv. Testing
- b. Work-up for neovascular glaucoma
 - i. Based on etiology
- c. In-office management – prior to referral
 - i. IOP control
- d. Triage for neovascular glaucoma
 - i. Retina
 - ii. Glaucoma
 - iii. PCP / ED
- e. Treatment of neovascular glaucoma
- f. Conclusion
- g. Q&A

Notes

The Suprachoroidal Space in Glaucoma Management

Christine L. Larsen, M.D.

- a. The suprachoroidal (or supraciliary) space
 - i. Anatomy
 - 1. Uveoscleral outflow pathway
 - 2. Cleft
 - a. Etiology
 - i. Trauma
 - ii. Iatrogenic
 - iii. Surgical
 - b. Treatment
 - i. Medical
 - ii. Laser
 - iii. Surgical
 - ii. Accessing the suprachoroidal space to lower IOP
 - 1. Surgical creation of a cleft
 - 2. Historical Devices
 - a. Ab Externo
 - i. Gold Micro-Shunt
 - ii. STARflo
 - iii. Aquashunt
 - b. Ab Interno
 - i. Cypass Micro-Stent
 - ii. iStent Supra
 - 3. Devices Under Investigation
 - a. CycloPen
 - b. MINInject
 - i. Current research opportunity for patient

Notes

Glaucoma and Pregnancy

Clara M. Choo, M.D.

Notes

a. Pre-conception counseling

- i. Women of childbearing age using glaucoma medications should be warned that none of the medications have FDA category A recommendation.
- ii. Eye development begins at week 3 and continues throughout gestation.
- iii. Ideally, the discussion of how glaucoma will be management during pregnancy happens before conception

b. Examination and monitoring

- i. Intraocular pressures typically lower in healthy eyes but can be variable in glaucomatous eyes.
- ii. Monitoring may need to be as frequent as once a trimester if there is more severe glaucoma.
- iii. Examination drops
 1. Punctal occlusion upwards of 2 minutes with drop administration if deemed necessary for exam. All examination drops are category C, but no definitive adverse events have been reported.
 2. Anesthetics: Topical anesthetics used in routine examinations are Category C.
 3. Mydriatics: Phenylephrine is Category C but used in obstetric anesthesia (treatment for hypotension related to spinal anesthesia). Phenylephrine 2.5% is thought to be well tolerated given systemic use. 10% strength may increase hypertension.
 4. Anticholinergics: Category C. Consider neonatal dosing (0.2% cyclopentolate, 0.5% tropicamide) if needed.

c. Medication Therapy

i. Brimonidine

1. Brimonidine is the only Category B drug (no evidence of risk to humans). It is considered first line therapy for all trimesters, but there should be plans to discontinue the medication a few weeks prior to delivery (week 36-37) and during lactation due to CNS depression effect on the neonate.

ii. Beta Blockers

1. Beta Blockers are Category C drugs. It is used systemically to manage maternal hypertension, but animal studies have shown teratogenicity. May be considered 2nd line therapy to be used with brimonidine.
2. First line therapy in post-partum period (if neonate does not have cardiac issues).



iii. Carbonic Anhydrase Inhibitors

1. Topical CAIs are Category C and 3rd line therapy, with limited systemic absorption. Systemic CAIs should be avoided due to teratogenicity in animal studies.

2. Can be used during lactation.

iv. Prostaglandins

1. Prostaglandins are Category C and 3rd line therapy. It can cause contractions of uterine muscle, and is used as an abortion induction agent in the first trimester.

2. Can be used during lactation.

v. Laser therapy

1. Selective Laser Trabeculoplasty and Laser Peripheral Iridotomy

a. No known risk to fetus. These lasers can be useful in reducing use of topical medications before conception.

2. Cyclophotocoagulation

a. These are shorter procedures that require a limited amount of local or systemic anesthesia.

vi. Surgical Therapy

1. Second trimester may be the best time to consider surgical therapy. The first trimester has higher risks to fetal anesthetic exposure. The third trimester may become more difficult with maternal positioning and maternal/fetal hypotension.

2. MIGS therapies may be explored given smaller incision sites and shorter surgical times/recovery periods.

3. Mitomycin C and 5-fluorouracil are known teratogenics. These agents are peri-operatively and post-operatively used in trabeculectomy surgeries.

4. Valsalva during labor may put post-surgical patients at risk for hypotony and choroidal detachments, especially if the patient has had a trabeculectomy or tube shunt. C-section should be discussed with the obstetrician.

Tube Shunts in Glaucoma Care

Notes

Patrick J. Riedel, M.D.

a. Current tube shunts (most common)

i. Baerveldt (J&J Vision):

1. 350 mm²

2. 250 mm²

ii. Ahmed (New World Medical)

1. FP7

2. FP8

3. S2

4. ClearPath 250 mm²

5. ClearPath 350 mm²

b. How do they work?

i. Shunt aqueous from anterior chamber to sub-conjunctival space via tube

ii. Tube shunt plate allows for reservoir formation in sub-conj/sub-tenons space

iii. Flow through tube should be controlled

1. Valved tube shunt device

2. Temporary closure/ligation of tube

c. When should they be used?

i. Can be used as primary trans-scleral filtering surgery

1. Neovascular glaucoma

2. Uveitic glaucoma

3. Post-traumatic glaucoma

4. Patients requiring simultaneous or near-term corneal transplant surgery

5. Aphakic patients

6. Significant conjunctival scarring from non-glaucoma surgery

ii. More often used after other glaucoma surgeries fail or are insufficient

iii. Allow option to be placed inferiorly, unlike other filtering surgeries

Notes

d. What are their advantages/disadvantages?

i. Advantages

1. Avoid surgical limbus which often is scarred
2. Allow an option after other sub-conjunctival incisional surgeries have been performed
3. Can be placed anywhere 360° on the eye
4. Proven effective at lowering IOP
5. More than one can be placed
6. Can be used in inflamed eyes

ii. Disadvantages

1. Large piece of permanent “hardware”
2. Failure
3. Corneal edema
4. Diplopia
5. Erosion

e. What studies support the use of tube shunts in glaucoma surgical management?

i. Trab versus Tube study (TVT)

ii. Primary Trab versus Tube (PTVT)

iii. Ahmed versus Baerveldt study (ABC)

iv. Ahmed versus Baerveldt study (AVB)

f. How do you care for post-operative tube shunt patients?

i. Early post-op period (first 4 weeks post-op)

ii. Intermediate post-op period (1-2 months post-op)

iii. Late post-op period (>2 months post-op)

Minnesota Eye Consultants Glaucoma & Cataract Specialist

Notes

Thomas W. Samuelson, M.D.

- a. Financial Disclosures
- b. Glaucoma Diagnostics; Drugs and drug delivery
- c. What is the primary method of IOP measure used in your office?
 - i. Goldman applanation
 - ii. Handheld digital device (tonopen, iCare, pneumotonometer)
- d. Results:
 - i. Correlation between home and Goldman was 0.99 (p< 0.001)
 - ii. Goldman showed excellent correlation
 - iii. Bias toward Goldman being higher than Home over a large range of IOP
- e. Visual Field Testing
 - i. Recommend 10-2 visual field testing
 - 1. In addition to or instead of 24-2
 - ii. What is your go-to testing format?
 - iii. When 10-2?
 - iv. When size V?
- f. OCT/Imaging
 - i. Recommended NFL and GCL/ macula
 - ii. Do you image both NFL and GCL?
 - iii. Which becomes abnormal first?
 - iv. If lack of correlation, which do you rely on more?
 - v. Is one of the other more susceptible to artifact?
- g. Medication Pitfalls
 - i. Compliance
 - ii. Follicular conjunctivitis
 - iii. Punctate staining
 - iv. Hyperemia
 - v. Corneal verticillate
 - vi. Corneal edema

- h. Potential “pre-surgical” therapies:**
 - i. Eye drop therapy**
 - ii. Laser therapy**
 - iii. Intracameral/sustained release- procedural therapeutics**
- i. Surgical management of Cataract and Glaucoma**
 - i. Cataract and mild to moderate, stable glaucoma**
 - 1. More often than not, preferred procedure is phaco plus**
 - a. iStent**
 - b. Hydrus**
 - c. Excisional goniotomy**
 - d. Canaloplasty**
 - e. Incisional goniotomy + canaloplasty**
 - f. Canal stent + viscodilation**
 - g. Bleb forming surgery**
 - h. ECP or micropulse**
 - ii. Standalone MIGS**
 - 1. Glaucoma Therapies**
 - a. SLT**
 - b. Eyedrop therapy**
 - c. Procedural therapeutic**
 - d. Micropulse laser**
 - e. Cataract surgery**
 - f. Canal based MIGS**
 - g. Transcleral surgery**
 - iii. How do you know when to intervene surgically?**
 - iv. Must we exhaust laser or pharma options first or can MIGS be used as alternative to meds?**
 - v. Are canal-based interventions less effective with more advanced disease?**
 - 1. Stenting vs. incisional vs excisional vs canal dilation**
- j. Surgical Management of Severe Glaucoma**
 - i. How often have you heard this statement?**
 - 1. Trabeculectomy is the gold standard procedure for glaucoma?**
 - ii. Glaucoma management=**
 - 1. Risk mitigation, no matter what we do, there is risk**
 - iii. Disease risk=**
 - 1. Mild, asymptomatic -> severe, blinding**
 - iv. Surgical risk=**
 - 1. Risk of disappointment -> catastrophic**
 - v. Trabs and tubes are still quite relevant**



SESSION TWO

Moderators



Mark S. Hansen, M.D.

Minnesota Eye Consultants
Cornea, Glaucoma, Cataract
& Refractive Specialist



Omar E. Awad, M.D., F.A.C.S

Minnesota Eye Consultants
Cornea, Cataract
& Refractive Specialist



Sherman W. Reeves, M.D., M.P.H.

Minnesota Eye Consultants
Cornea, Cataract
& Refractive Specialist

Panelists



**Elizabeth A. Davis,
M.D., F.A.C.S.**

Minnesota Eye Consultants Cornea,
Cataract & Refractive Specialist



**David R. Hardten,
M.D., F.A.C.S.**

Minnesota Eye Consultants Cornea,
Cataract & Refractive Specialist



**Matthew Field, M.D.,
Ph.D., M.P.H.**

Minnesota Eye Consultants
Ophthalmic Fellow

Navigating Diagnostic and Therapeutic Challenges in Cataract Patients

COPE Course ID # 90871-PO

Course Description

This course will present a variety of diagnostic and therapeutic problems in regard to the patient presenting with cataract symptoms in a case based, panel discussion format.

Course Objective

1. Case-based diagnosis of cataracts, perioperative concerns and intraocular lens options for the cataract patient will be presented.
2. Panel discussion of therapeutic and management options of these conditions will be discussed.

Navigating Diagnostic and Therapeutic Challenges in Cataract Patients

Mark S. Hansen, M.D.; Omar E. Awad, M.D., F.A.C.S; Sherman W. Reeves, M.D., M.P.H.

Panelists:

Elizabeth A. Davis, M.D., F.A.C.S.

David R. Hardten, M.D., F.A.C.S

Matthew Field, M.D., Ph.D., M.P.H.

1. Cataract panel
 - a. Faculty Disclosures
 - b. Overview
2. Case 1: Cataract in a post-LASIK patient
 - a. Presentation:
 - i. 58 year old female
 1. History of LASIK
 - a. Now with night driving halos
 - b. BCVA 20/25 with BAT to 20/50 OU
 - c. 1+PSC OU on exam
 - d. Doesn't want to wear glasses for distance or near vision
 - e. Audience Response Questions
 - ii. Preoperative history concerns:
 1. Are prior refractive records needed?
 1. Yes?
 2. No?
 - ii. Monovision history?
 - c. Exam findings
 - d. Special testing:
 - i. Role of corneal topography/tomography
 - ii. Post-LASIK calculations
 - e. Special counseling for post-LASIK status
 - i. Setting expectations
 1. Over/under correction possibility
 - ii. Understanding of accuracy post corneal refractive surgery

Notes

Notes

- f. IOL options and counseling
 - i. Standard vs. premium options
 - ii. Which premium IOL to use
- g. Postoperative concerns
 - i. Dealing with residual refractive error
 - ii. Enhancement strategies
- h. Panel discussion
- 3. Case 2-Cataract with concurrent corneal disease
 - a. Presentation:
 - i. 78-year-old male
 - 1. Harder to see the TV
 - 2. BCVA 20/40 OU
 - 3. 3+ NS with guttata OU
 - ii. Audience response questions
 - b. Preoperative history concerns
 - i. Symptomatic from Fuchs
 - 1. Morning blur?
 - ii. Family history?
 - c. Exam findings/Special testing
 - i. Role of specular microscopy
 - ii. Role of CCT
 - d. IOL options and counseling
 - i. Cataract surgery alone or combined with DMEK
 - ii. What IOL's to offer
 - e. Postoperative concerns
 - i. Approach to postop corneal edema
 - f. Panel discussion



SESSION ONE



**David R. Hardten,
M.D., F.A.C.S.**

Minnesota Eye Consultants Cornea,
Cataract & Refractive Specialist



**Elizabeth A. Davis,
M.D., F.A.C.S.**

Minnesota Eye Consultants Cornea,
Cataract & Refractive Specialist

Advancements in the Treatment of Keratoconus

COPE Course ID # 90872-PO

Course Description

This course will review the treatments for keratoconus as well as introduce a new surgical modality for treatment called ALKRS (Automated Lamellar Keratoplasty using Regional Segments). The audience will learn about the indications, procedure, and postoperative course for patients having ALKRS.

Course Objective

1. Understand the current treatment options for keratoconus
2. Learn about the newest surgical treatment option
 - a. Indication
 - b. Surgical procedure
 - c. Postoperative management
 - d. Outcomes



Advancements in the Treatment of Keratoconus

David R. Hardten, M.D., F.A.C.S.

Elizabeth A. Davis, M.D., F.A.C.S.

1. Financial Disclosures

2. Legacy of Keratoconus Patients

a. PK for KCN

i. Long history of PK for KCN

ii. Because of large grafts, often iris issues, failed grafts

iii. Newer management strategies for KCN hopefully will prevent late need for repeat PK, anterior segment reconstruction, glaucoma surgeries, scleral fixated IOLs

iv. Identify & Manage Early (Avoid Progression with Progressive Disability)

3. Alternatives for KCN

a. KCN – Avoid PK or DALK

i. Improving options now with crosslinking and ALKRS (CAIRS, CTAK)

ii. This patient had ALKRS and Crosslinking

iii. Scleral Lenses can still be used

4. ALKRS

a. Anterior Lamellar Keratoplasty with Regional Segments

i. Also known as CAIRS (similar to Intacs but with corneal tissue)

ii. Discuss customized corneal tissue segments (CTAK)

iii. Crosslink after

5. Corneal Collagen Crosslinking

a. Mechanism of Action

i. Riboflavin excited by UVA radiation into triplet state, generating reactive oxygen species

ii. Reactive oxygen species create covalent bonds between collagen molecules

6. Effects of Corneal Cross-Linking

7. Collagen Crosslinking

a. Procedure Details

i. Good full saturation with Riboflavin using KeraFlow irrigation device

ii. Usually takes 5-10 min to saturate after epithelium removed

iii. 30 min of light 3mW/cm²

iv. Artificial Tears every 10-12 minutes to prevent desiccation

Notes



MINNESOTA EYE
FOUNDATION

8.CXL

- a. Good full saturation with Riboflavin using KeraFlow irrigation device
- b. Usually takes 5-10 min to saturate after epithelium removed
- c. 30 min of light 3mW/cm²
- d. Artificial Tears every 10-12 minutes to prevent desiccation
- e. Expected 1 week post-operative findings
 - i. Epi defect should be healed by 1 week
 - ii. Bandage soft contact lens can come out 1-7 days postop
 - iii. If still epi defect at one week, then likely will heal better without contact lens due to curvature issues
 - iv. Frequent non-preserved lubricants

f.CXL – Visit Schedule

i. Early Postoperative

1. 1-day post-op visit:

2. 4-to-7-day post-op visit:

3. 1 Month visit:

- a. Vision and pressure – epi should be back to normal, mild dryness, make sure hasn't had steroid response – separate visit related to keratoconus, not specifically to surgery

4. 2–3-month visit – Might benefit from refit contact lens

5. Recommend topography at 3 months, 6 months, then every 6 months in patient under 30 to monitor for keratoconus stability, annual if over age 30

9.IEK – Femtosecond Enabled Keratoplasty

a. Lamellar or Penetrating Keratoplasty

- i. Useful for large degrees of ectasia
- ii. Patients unable to wear contacts
- iii. Patients not having good results with CXL or Intacs/CK

10. Deep Anterior Lamellar Transplant

a. Anterior

- i. Partial thickness transplant for patients with anterior corneal disease
- ii. Keratoconus & post-refractive surgery ectasia
- iii. Anterior corneal scars
- iv. Technique

1. Dissect off anterior cornea of patient – leaving Descemet's membrane

2. Dissect off Descemet's from donor

3. Then suture transplant onto patient over Descemet's membrane

4. Suturing similar to that of a PK

Notes

11. Case Study: KCN
 - a. 39-year-old with KCN OU
 - b. OD: $-12.5 + 8.00 \times 175 = 20/50$
 - c. Pach 378
 - d. 20/30 in contacts & difficult to wear
12. Case Study: KCN
 - a. 41-year-old
 - b. 2 years after DALK with IEK OD
 - c. $-2.25 + 3.25 \times 105 = 20/20$
 - d. Still occasionally wears RGP
13. Diagnose Early/Monitor Closely
 - a. 11-year-old with asymmetric astigmatism
 - i. Stable for 2 subsequent exams 6 months apart
 - ii. Still need close monitoring – thin, slight asymmetry, KCN suspect
 - iii. Subtraction mapping – picks up subtle abnormalities/changes (N-O)
14. Diagnose Early/Cross-Link Early
 - a. 14-year-old first exam with definite KCN
 - i. “Normal” eye exam 2 years ago
15. KCN – Intolerant of Contacts
 - a. Shape Change with Intacs/CK/CXL
 - i. 36yo, contact lens intolerant, mild progression, poor vision in glasses
 - ii. Pre
 - iii. Post
16. KCN – Intolerant of Contacts: Supplement
 - a. Shape Change with Intacs/CK/CXL
 - i. 37yo, now contact lens tolerant (20/20), 20/25 in glasses
17. Should Intacs Still Play a Role?
 - a. KCN
 - i. Shape change and improve vision in glasses
 - ii. More difficult to fit contacts afterwards
 - iii. I think ALKRS/CAIRS/CTAK should replace Intacs in all of our patients now
 - iv. ALKRS can now be used even in contact lens tolerant patients who want improved fit and occasional glasses wear
18. CTAK: Tissue and Plan
 - a. Surgeon identifies candidate
 - b. Sends raw data from Pentacam
 - c. Planning and tissue provided
 - i. Tissue thickness
 - ii. Tissue width
 - iii. Tissue length
 - iv. Depth
 - v. Incision angle
 - vi. Offset
 - vii. Tissue orientation

19. KeraNatural

- i. 2-year shelf life
- ii. Full thickness cornea
- iii. Either half-moon segment or full ring size
- iv. 6mm or 8 mm diameter
- v. EBAA Accredited

b. Surgeon plans treatment based on Pentacam, topo, pachymetry

- i. Trims segment to appropriate length
- ii. Trims segment as desired
- iii. Laser data entry:
 - 1. Center offset is manually done by surgeon.
 - 2. Can mark center prior to application of Intralase cone

c. Splitting Tissue

- i. Comes as the original donor thickness – so – can split if need thinner tissue (usually for less hyperopic shift)

20. ALKRS Case 1

- a. OM - 21yo M OS, KCN (Milder OD)
 - i. Pre: UCVA: 20/250, $-6.75 + 3.75 \times 0.63 = 20/40$
 - ii. 3mo: UCVA: 20/40, $-1.5 + 3.25 \times 1.60 = 20/20$
 - iii. 4mo: Scleral Lens: 20/20
 - iv. Pre

21. ALKRS Case 1 Plan: 4-8mm, InfTemp: 2.3mm, 115 incision, 200-micron depth, 300 micron thick, 260 degree length

- a. OM - 21yo M OS, KCN (Milder OD)
 - i. Pre: UCVA: 20/250, $-6.75 + 3.75 \times 0.63 = 20/40$
 - ii. 3mo: UCVA: 20/40, $-1.5 + 3.25 \times 1.60 = 20/20$
 - iii. 4mo: Scleral Lens: 20/20
 - iv. Pre vs 3 months, subtractions @ 2 months

22. ALKRS Case 2

- a. MJ - 41yo F OD > OS
 - i. Pre: UCVA: 20/30, $-6.0 + 7.75 \times 1.21 = 20/30$
 - ii. 3mo: UCVA: 20/40, $-0.25 + 1.25 \times 1.08 = 20/20$
 - iii. Pre

23. ALKRS Case 2 Plan: 4-8mm, InfTemp: 2.3mm, 110 incision, 200-micron depth, 350 micron thick, 230 degree length

- a. MJ - 41yo F OD > OS
 - i. Pre: UCVA: 20/30, $-6.0 + 7.75 \times 1.21 = 20/30$
 - ii. 3mo: UCVA: 20/40, $-0.25 + 1.25 \times 1.08 = 20/20$
 - iii. Pre vs 3 months postop (Humphrey Topo Post only)

Notes

24. ALKRS Case 3: 4.5-7.5mm, InfTemp:2.3mm, 55
incision, 250-micron depth, 200-micron thick, 180
degree length
- a. JG - 40yo M OD>OS, Post-M-LASIK Ectasia
 - i. Pre: UCVA: 20/250, $-4.75+2.25 \times 153 = 20/20$
 - ii. 3mo: UCVA: 20/50, $-0.5+4.75 \times 122 = 20/20$
 - iii. Pre vs 3 months post
25. ALKRS Case 4: 4.0-8.0mm, InfTemp:2.2mm, 113
incision, 200 micron depth, 250 micron thick, 220
degree length
- a. PD - 28yo F OD
 - i. Pre: OD: UCVA: 20/60, $-3.25+2.75 \times 167 = 20/25$
 - ii. 3mo: OD: UCVA: 20/30, MR: $-1.25 \text{Dsphere} = 20/20$
 - iii. Pre vs 3mo
26. ALKRS Case 5: 4.0-8.0mm, InfTemp:1.8mm, 067
incision, 200 micron depth, 200 micron thick, 250
degree length
- a. JS - 32yo F OD
 - i. Pre: UCVA: 20/40, $-1.25+1.75 \times 163 = 20/25$
 - ii. 3mo: UCVA: 20/20, plano+0.5x105=20/15
 - iii. Pre vs 3 months
27. ALKRS Case 6:
- a. OI - 25yo M OS
 - i. Pre UCVA: 3/200E
 - ii. Pre MR: $-9.00+4.00 \times 41 = 20/100$, J16
 - iii. Pre op topo:
28. ALKRS Case 6
- a. Plan 4.0-8.0mm, InfTemp:2.13mm, 061 incision,
200 micron depth, 450 micron thick, 300 degree length
 - b. 4 mo. Postop
 - i. UCVA: 20/80
 - ii. BCVA: 20/40, J2
 - iii. Ks: 22.4 D flattening
 - iv. $(65.5/62.69 \rightarrow 43.51/41.88)$
29. ALKRS Case 7:
- a. KW - 33yo M OD
 - i. Pre: UCVA: 3/200E, J16
 - ii. No MR gives improvement
 - iii. Although no scarring, probably a good
keratoplasty candidate at this level of steepening
30. ALKRS Case 7:
- a. Width 4.0-8.0 mm, Inf-Temp Offset (due to
thinning) 2.0 mm, Depth 200 microns, Thickness 454
microns, Length 330 degrees
 - b. 7 months:
 - i. UCVA: 20/80, J14
 - ii. MR: $-1.00+1.50 \times 59$
 - iii. BCVA: 20/40, J3
 - iv. Average Ks: 49.89 D
 - v. Flattening: 38.61 D
 - vi. Currently being fit with sclerals

31. Billing/Coding Information: Keratoconus
 - a. Progressive (unstable) – H18.62
 - b. Irregular Astigmatism – H52.211,2,3
 - c. Difficulty with glasses and contact lenses
 - d. CXL: 0402T
 - e. ALK: 65730 and Tissue: V2785
32. Drop Regimen: ALKRS
 - a. Same as CXL Drop Regimen
 - i. Abx QID until gone
 - ii. Pred Forte QID 3 wks, TID 3wks, BID 3wks, qd 3wks
 - iii. NSAID QID 1d, TID 1d, BID 1d, qd 1d
 - iv. Muro ointment night after BSCL out for 6-12 months
 - v. Vit C 1gm 3 months AFTER surgery
 - vi. Norco
 - vii. Neurontin or Lyrica
33. Current Thoughts On Criteria
 - a. KCN Treatments
 - i. Recognize no hard cut-offs for treatment guidelines or algorithms, patient discussion is key
 - b. Young Patient: Observation – Yearly
Topography/Tomography:
 - i. Changing astigmatism without inferior steepening
 - ii. Strong family history
 - iii. Down's syndrome, atopic disease, or other genetic risk factors
 - c. Older Patient: Observation – Yearly
Topography/Tomography:
 - i. No progression in last few years
 - ii. Good vision and contact lens tolerance
 - iii. Age over 40-50
 - iv. Good about eye rubbing and sleep position
 - d. CXL alone
 - i. Good BCVA/UCVA in typical method of correction: glasses/contacts, comfortable fit and age at risk for progression (<50yo)
 - ii. Recognize no hard cut-offs for treatment guidelines or algorithms, patient discussion is key
 - e. ALKRS+CXL
 - i. Poor UCVA or BCVA in glasses and Poor/uncomfortable fit in contacts
 - ii. Unacceptable vision in contacts
 - iii. Difficulty manipulating contacts
 - iv. Strong aversion to wearing contacts
 - f. DALK/PK
 - i. Centrally visually significant scar that doesn't give acceptable vision in contacts
 - ii. Cornea too thin to place ALKRS (250 microns at a 5mm optical zone)

34.ALKRS: Current Thoughts on Outcomes

- a. Which patients/eyes have biggest change in flattening?
 - i. Like CXL, patients with the steepest and thinnest corneas will have the greatest change in flattening.
 - ii. In general, age does not seem to be a factor.
 - iii. The thicker the inserted tissue and the longer the segment, the more change will occur as well.
- b. What types of corneal topographies have best improvements in BCVA?
 - i. Asymmetric cones (inferior steepening) seem to have the greatest improvements.
 - ii. However, symmetric cones also do see benefit.
- c. Results when done after CXL
 - i. Still of benefit.
 - ii. Good for patients who aren't getting adequate VA with CLs/sclerals after previous CXL.

35.Q&A

THANK YOU TO OUR EXHIBITORS

GOLD EXHIBITOR

Alcon

SEE BRILLIANTLY



CHERRY
OPTICAL LAB

See the difference.

The Minnesota Eye Foundation is a 501(c)(3) non-profit organization created in 2005 to enrich the quality of life of individuals living throughout the Twin Cities and greater Minnesota through charitable outreach and education.